

# Southern Plastic Surgery

PLASTIC, HAND & COSMETIC SURGERY

Tuesday, 17 December 2019

NDIS  
GPO BOX 700  
CANBERRA ACT 2601

To: National Assessment Team

Re: Mr Natham Raco, 72 Vida Street, Aberfeldie 3040, DOB: 06/04/93  
REFERENCE NO. 431377621

Please find below answers to specific questions regarding Natham's function and mobility.

Mobility: Can walk normally. Has restricted upper limb and hand function

Communication: Normal

Social interaction: Normal

Learning: Normal

Self Care: Needs aids to assist with personal care, hygiene, grooming - including showering, bathing, dressing, eating, toileting, caring for own health care needs.

Self-Management: Normal.

With kind regards,



Prof Christopher Coombs MBBS(Hons) FRACS  
Clinical Professor, University of Melbourne  
Plastic Hand and Cosmetic Surgeon - 033897AW  
Chief, Plastic and Maxillofacial Surgery,  
Royal Children's Hospital, Melbourne.

**Prof. Christopher Coombs**

FRACS (Head)  
Provider No. 33897AW  
Email: [chris@southernplasticsurgery.com.au](mailto:chris@southernplasticsurgery.com.au)

**Dr. Jane M. Thompson**

MBBS, MD  
Provider No. 292527X  
Email: [jane@southernplasticsurgery.com.au](mailto:jane@southernplasticsurgery.com.au)

[www.southernplasticsurgery.com.au](http://www.southernplasticsurgery.com.au)

863 Hampton Street  
Brighton 3186  
Tel: 0591 0714  
Fax: 9593 3514

Esclave Pty Ltd ABN 27 069 473 578

**ASPS**

20th December 2019



**Assoc. Professor  
David McCombe**  
MBBS MD FRACS  
Hand, Plastic & Reconstructive  
Surgery

**St Vincent's Hospital**  
Suite C37 Level 3  
Building C  
41 Victoria Parade  
Fitzroy Vic 3065  
Phone (03) 9412 8820  
Fax (03) 9412 8801  
david.mccombe@vhsa.com.au  
Pager (03) 9387 1000

Provider No 094946FF  
ABN: 74 223 343 919

To whom it concerns,

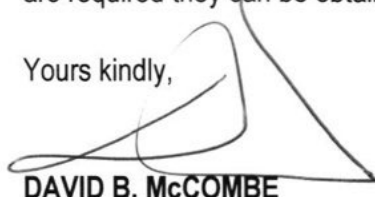
**Re: Mr Natham Raco, D.O.B. 06/04/93  
72 Vida Street Aberfeldie 3040**

Mr Raco has been a patient of this practice from 2013 and prior to this I was involved in Natham's care through the Hand Clinic at the Royal Children's Hospital. Natham is currently a 26-year-old left-handed man with arthrogryposis. The consequence of the congenital condition is marked restriction of function with both upper limbs. He has restricted range of motion of the shoulder and elbow, wrist and hands which limit his capacity of function in all domains of upper limb function significantly. He has had undergone multiple procedures including complex surgery such as free muscle transfer to improve elbow flexion and a partial wrist arthrodesis on the left side together with multiple tendon transfers and contracture releases however remains significantly compromised with respect to his ability to grasp, operate a keyboard, reach, perform activities of daily living and similarly domestic and social activities. This is a permanent condition and as has been evident with progression over time, there has been premature arthritis develop in his wrists and he is currently considering further surgery to address this on the basis of pain and disability.

Any future surgery is also likely to compromise his range of motion function in the hands and contribute further to compromise of function.

Mr Raco also has core strength and lower limb issues associated with this congenital condition and I would support his application for support from the NDIS. If further details are required they can be obtained from this office with written patient permission.

Yours kindly,



**DAVID B. McCOMBE**